

# Endothelial Cell Loss and Surgically Induced Astigmatism After Sutureless Large-Incision Manual Cataract Extraction (SLIMCE)

Dennis S. C. Lam, MD, FRCOphth; Srinivas K. Rao, FRCS; Alex H. Fan, MRCSEd, MMed, Ophth; Nathan G. Congdon, MD, MPH; Victoria Wong, MMedSc, MRCS; Yingpeng Liu, MD; Philip T. H. Lam, FRCS, FRCOphth

**Objectives:** To describe a modified manual cataract extraction technique, sutureless large-incision manual cataract extraction (SLIMCE), and to report its clinical outcomes.

**Methods:** Case notes of 50 consecutive patients with cataract surgery performed using the SLIMCE technique were retrospectively reviewed. Clinical outcomes 3 months after surgery were analyzed, including postoperative uncorrected visual acuity, best-corrected visual acuity, intraoperative and postoperative complications, endothelial cell loss, and surgically induced astigmatism using the vector analysis method.

**Results:** At the 3-month follow-up, all 50 patients had postoperative best-corrected visual acuity of at least

20/60, and 37 patients (74%) had visual acuity of at least 20/30. Uncorrected visual acuity was at least 20/68 in 28 patients (56%) and was between 20/80 and 20/200 in 22 patients (44%). No significant intraoperative complications were encountered, and sutureless wounds were achieved in all but 2 patients. At the 3-month follow-up, endothelial cell loss was 3.9%, and the mean surgically induced astigmatism was 0.69 diopter.

**Conclusions:** SLIMCE is a safe and effective manual cataract extraction technique with low rates of surgically induced astigmatism and endothelial cell loss. In view of its low cost, SLIMCE may have a potential role in reducing cataract blindness in developing countries.

*Arch Ophthalmol.* 2009;127(10):1284-1289

**C**ATARACT REMAINS THE leading cause of blindness in developing countries. More than 19 million people, representing 43% of all blindness in the world, are bilaterally blind because of cataract.<sup>1</sup> This has led the World Health Organization's Global Vision 2020 initiative to call for a dramatic increase in the volume of cataract surgical procedures worldwide.<sup>2</sup>



Video available online at [www.archophthalmol.com](http://www.archophthalmol.com)

Unfortunately, multiple barriers have adversely affected the availability of cataract surgical services in developing countries. These include a lack of affordable services<sup>3</sup> and poor surgical outcomes.<sup>4-8</sup> A reasonable strategy to overcome these barriers is to provide high-quality affordable cataract surgical procedures at locations close to where people live. A well-designed cataract surgical procedure is needed that provides rapid postoperative visual rehabilitation and is low cost, easy to perform, safe and effective, and independent of phacoemulsification machines.

None of the commonly performed cataract surgery techniques, namely, phacoemulsification, manual extracapsular cataract extraction (ECCE), or manual small-incision cataract surgery (SICS), satisfy all of these criteria. Phacoemulsification involves high initial capital investment and consumable costs. Manual ECCE involves a large 10- to 11-mm-long surgical wound that increases the chance of potentially serious intraoperative complications, requires suturing, lengthens surgical time, and slows postoperative visual recovery. Manual SICS is the most commonly used technique among high-volume cataract centers in developing countries.<sup>9-14</sup> It can be performed quickly and in high volume by experienced hands. To achieve a self-sealing wound, a small scleral incision (6-6.5 mm) is combined with a long sclerocorneal tunnel for nucleus delivery. While this wound may be sufficient for cataracts of mild to moderate density, hard large nuclei, which are common in populations with poor access to surgical services, may induce undue trauma to intraocular tissues. Moreover, considerable microsurgical expertise is required, and a longer learning curve may be involved.

Sutureless large-incision manual cataract extraction (SLIMCE) is a modified manual cataract extraction technique that

**Author Affiliations:** Department of Ophthalmology and Visual Sciences, The Chinese University of Hong Kong, Hong Kong Eye Hospital, Kowloon (Drs D. Lam, Rao, Fan, Congdon, Wong, and P. Lam) and Joint Shantou International Eye Centre of Shantou University, The Chinese University of Hong Kong, Shantou, China (Drs D. Lam, Rao, Congdon, and Liu).

was specially designed by one of us (D.S.C.L.) to fulfill the requirements of an ideal cataract surgery to be used in high volumes for reducing cataract blindness in developing countries. The salient features of this modified technique include the following (1) a large scleral incision (8-mm linear length) for safe and easy nucleus delivery, (2) a long sclerocorneal tunnel (4 mm) for achieving a sutureless but self-sealing wound,<sup>15</sup> (3) a posterior incision position (2 mm posterior to the limbus) and a frown-shaped wound configuration for astigmatic neutrality,<sup>16,17</sup> and (4) the use of an anterior chamber (AC) maintainer to assist nucleus delivery.<sup>18</sup>

We report the clinical outcomes of the SLIMCE technique, including endothelial cell loss and surgically induced astigmatism (SIA). Its potential as a tool to reduce cataract blindness in developing countries is also discussed.

## METHODS

### STUDY DESIGN

Case notes were retrospectively reviewed of 50 consecutive patients who underwent SLIMCE surgery performed by a single experienced surgeon (D.S.C.L.) between November 29, 2004, and December 7, 2004, and who completed a 3-month follow-up schedule. These patients had uncomplicated age-related cataract without any ocular comorbidities that might alter vision or corneal abnormalities that might affect corneal topography measurements. The tenets of Declaration of Helsinki were followed, and informed consent was obtained from each patient before surgery. The study was approved by the Institutional Review Board of the Hong Kong Eye Hospital.

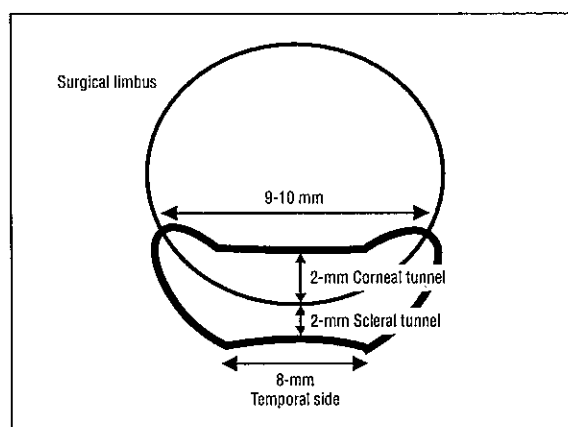
Intraocular lens (IOL) power was calculated according to preoperative keratometry (KR-7100; Topcon, Tokyo, Japan) and axial length (I000; UBP, Storz, Germany) measurements using the Sanders-Retzlaff-Kraff II formula. The target postoperative refraction was -1.0 diopter (D). A 7-mm-diameter nonfoldable single-piece polymethylmethacrylate IOL (CZ70BD; Alcon Laboratories Inc, Fort Worth, Texas) was implanted in all patients.

Patients were seen before surgery and at 1 day, 1 week, 1 month, and 3 months after surgery. Besides complete ophthalmic examinations, including dilation of the pupil at each visit, specular microscopy (SP 8000; Konan Medical Inc, Tokyo, Japan) and corneal topography (Orbscan III; Bausch & Lomb Inc, Rochester, New York) were performed before surgery and 3 months after surgery. Best-corrected visual acuity (BCVA) was measured 3 months after surgery.

The specular microscopy results, which were obtained by selecting 100 adjacent cells for calculation before surgery and 3 months after surgery, were used to determine surgically induced endothelial cell loss.<sup>19,20</sup> After confirming the normality of preoperative and postoperative endothelial cell density distributions, paired-sample *t* test was used to compare the means. *P* < .05 was regarded as statistically significant.

Surgically induced astigmatism was also studied. The degree was calculated using the vector analysis method described by Holaday et al<sup>21</sup> based on the keratometry results of corneal topography examinations before surgery and 3 months after surgery.

Postoperative visual acuity was classified as at least 20/60 (good outcome), 20/80 to 20/200 (borderline outcome), or less than 20/200 (poor outcome) according to the World Health Organization's Prevention of Blindness Program guidelines.<sup>5</sup> For patients with postoperative BCVA of at least 20/60, the proportion with visual acuity of at least 20/30 was also analyzed. Postoperative subjective refraction was compared with preop-



**Figure 1.** Details of the temporal main wound construction. The scleral incision is 8 mm in linear length, the funnel-shaped sclerocorneal tunnel is 4 mm in length (2 mm in the sclera and 2 mm in the clear cornea), the internal corneal wound opening is about 9 to 10 mm in length, and 2 side pockets are constructed for large nuclei.

erative target refraction. The incidence and nature of intraoperative and postoperative complications were also recorded.

### THE SLIMCE TECHNIQUE

All surgical procedures were performed using retrobulbar or peribulbar anesthesia. The temporal approach was used. A step-by-step guide of 10 components of the SLIMCE technique follows (a video is available online at <http://www.archophthalmol.com>).

#### Conjunctival Limbal Peritomy

Conjunctival limbal peritomy was started with two 3-mm oblique relaxation cuts at the 7- and 11-o'clock positions (for a right eye). This was followed by a 10- to 12-mm limbal peritomy.

#### Sclerocorneal Tunnel Construction

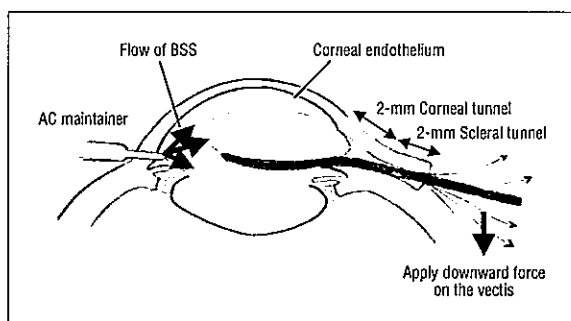
An 8-mm-long, frown-shaped, half-thickness scleral incision with its center 2 mm from the limbus was made with a 2.5-mm crescent knife (Xstar; BD, Franklin Lakes, New Jersey). Using the crescent knife, a 4-mm-long sclerocorneal tunnel was dissected from the scleral incision, extending 2 mm into clear cornea. A side pocket was created at each end of the incision to allow sufficient space for nucleus delivery (**Figure 1**).

#### Side Ports

As side ports, 3 paracentesis sites were created with a 15° slit knife. For a right eye, these were placed at the 3-, 6-, and 12-o'clock positions.

#### Capsular Stain and Capsulorrhexis

A few drops (0.6 mg/mL) of trypan blue (VisionBlue; Dutch Ophthalmic Research Center, Amsterdam, the Netherlands) were used to stain the AC under air. A dispersive viscoelastic agent (Viscoat, Alcon Laboratories Inc) was used to replace the air. A 3-mm keratome (Xstar) was introduced into the center of the tunnel, and the AC was entered. Anterior capsulorrhexis was performed using a pair of capsulorrhexis forceps or a bent 27-gauge needle. The capsulorrhexis was at least 6 mm in diameter for easy dislocation of the nucleus into the AC.



**Figure 2.** Nucleus delivery by vectis through the sclerocorneal tunnel is assisted by hydroexpression. If performed properly, the corneal endothelium (shown in red) can be spared from mechanical trauma throughout the process. AC indicates anterior chamber; BSS, balanced salt solution.

### Loosening the Nucleus

In most patients, conventional hydrodissection was performed to loosen the attachments of the nucleus to the capsular bag. Alternatively in some patients, a spatula was introduced into the cortical layer under the AC and swept within this layer, quadrant by quadrant, to produce a mechanical separation of the nucleus from the AC. Unlike conventional hydrodissection that may stir up cortical materials and obscure the view, such mechanical separation has the advantage of maintaining better visibility of the nucleus. However, there must be enough cortical material present for this intracortical maneuver to be safely performed, and care must be taken not to induce undue stress on the zonules.

### Nucleus Dislocation Into the AC

We used 2 Sinsky hooks.<sup>18</sup> The first hook engaged the nucleus at the junction between the distal and middle thirds of the anterior surface of the lens and gently moved the nucleus toward the incision; the other hook, was then passed under the capsulorhexis margin at the 3-o'clock position (for a right eye) and retracted the equator of the nucleus from the capsular fornx. With these maneuvers, the equator of the nucleus at the 3-o'clock position (in a right eye) was dislocated from the bag. The shoulder of the first hook then gently depressed the nucleus posteriorly over its midperipheral portion at the 9-o'clock position (in a right eye) so that the nucleus tumbled out of the bag.

### Nucleus Extraction

For nucleus extraction, a keratome was used to complete the internal entry across the entire length of the sclerocorneal tunnel. An AC maintainer was then inserted into the distal paracentesis wound. The bottle height was maintained at least 90 cm above the operating table to produce sufficient infusion pressure to assist in delivery of the nucleus. A vectis was then introduced through the sclerocorneal tunnel into the AC and under the lens. Once it was in position, the AC infusion was turned on. As the AC deepened, the lens was seated on the spoon of the vectis, and the whole vectis was gently pushed slightly posteriorly to reduce the risk of damage to the endothelium (**Figure 2**). Subsequently, the vectis was used to push down on the floor of the tunnel. Gentle pressure on the sclera from the forceps in the nondominant hand allowed the wound to open such that the hydrostatic pressure would push the nucleus toward the corneoscleral tunnel. Once the first quarter or half of the nucleus was engaged in the tunnel,

**Table 1. Distribution of Preoperative and 3-Month Postoperative Visual Acuity**

| Visual Acuity   | No. (%) of Patients (N=50) |               |         |
|-----------------|----------------------------|---------------|---------|
|                 | Preoperative               | Postoperative |         |
|                 | UCVA                       | UCVA          | BCVA    |
| ≥20/30          | 0                          | 28 (56)       | 37 (74) |
| 20/40 to 20/60  | 2 (4)                      |               | 13 (26) |
| 20/80 to 20/200 | 34 (68)                    | 22 (44)       | 0       |
| <20/200 to >FC  | 2 (4)                      | 0             | 0       |
| ≤FC             | 12 (24)                    | 0             | 0       |

Abbreviations: BCVA, best-corrected visual acuity; FC, finger counting; UCVA, uncorrected visual acuity.

gentle side-to-side rocking movements further aided the passage of the nucleus through the tunnel. Movement within the tunnel should be safe because the nucleus is away from the endothelium.

### Removal of Cortical Material

A 23-gauge aspiration cannula (Duckworth & Kent Ltd, Baldock, Hertfordshire, England) was initially used to clean the tunnel, allowing easy removal of large pieces of epinucleus. The remaining cortex was stripped through the 2 side ports.

### IOL Insertion

The AC was filled with a cohesive viscoelastic agent (ProVisc, Alcon Laboratories Inc). The first step was to insert the IOL into the sclerocorneal tunnel. The second step was to place the distal haptic and the entire optic into the capsular bag. In the third step, the proximal haptic was dialed into the bag using a Sinsky hook.

### Closure

With the AC maintainer infusion on, the residual AC viscoelastic agent was removed using the aspiration cannula. The side ports were hydrated, and the main wound was checked for leakage. Once watertight wound closure was ensured, the AC maintainer was removed, and the associated wound site was hydrated. The conjunctiva was repositioned, and cautery was used to secure it in place. Subconjunctival antibiotics and corticosteroids were injected away from the temporal wound to avoid displacing the conjunctiva. The eye was then patched with antibiotic ointment.

## RESULTS

Fifty eyes of 50 consecutive patients underwent the SLIMCE technique. Twenty-seven patients (54%) were male, and 23 patients (46%) were female, with a mean (SD) age of 73.3 (7.6) years (age range, 52-86 years).

The distribution of preoperative uncorrected visual acuity (UCVA) was as follows: finger counting or worse in 12 patients (24%), better than finger counting but less than 20/200 in 2 patients (4%), 20/80 to 20/200 in 34 patients (68%), and at least 20/60 in 2 patients (4%) (**Table 1**). No patients had preoperative UCVA of at least 20/50 in the operative eye.

**Table 2. Postoperative Complications and Their Management**

| Postoperative Complication                  | No. (%) of Patients | Management                                | Time to Resolution |
|---|---------------------|---|--------------------|
| Microscopic hyphema                         | 1 (2)               | Observation                               | <1 wk              |
| Transient hypotony                          | 1 (2)               | Eye patching                              | 1 d                |
| Transient corneal edema                     | 1 (2)               | Observation                               | <1 wk              |
| Transient elevation of intraocular pressure | 11 (22)             | Intraocular pressure-lowering medications | <1 d               |

**Table 3. Results of Preoperative and 3-Month Postoperative Specular Microscopy**

| Variable                                      | Mean (SD)     |                       | Change, % | P Value <sup>a</sup> |
|---|---------------|-----------------------|-----------|----------------------|
|   | Preoperative  | 3-Month Postoperative |           |                      |
| Endothelial cell density, per mm <sup>2</sup> | 2522 (483)    | 2424 (475)            | -3.9      | .03                  |
| Coefficient of variation                      | 0.376 (0.011) | 0.379 (0.011)         | -0.01     | .80                  |
| Hexagonal cells, %                            | 54.9 (1.5)    | 54.6 (1.6)            | -0.01     | .88                  |

<sup>a</sup>Two-tailed *t* test.

### POSTOPERATIVE VISUAL ACUITY AND REFRACTION

All patients had improved visual acuity after surgery. The distribution of UCVA 3 months after surgery was 28 patients (56%) with at least 20/60 (good outcome) and 22 patients (44%) with 20/80 to 20/200 (borderline outcome) (Table 1). None of the patients had postoperative UCVA less than 20/200 (poor outcome) in the operated eye.

After subjective refraction, all patients had BCVA of at least 20/60. Thirty-seven patients (74%) had BCVA of at least 20/30 (Table 1). Twenty-nine patients (58%) had improvement in Snellen visual acuity of at least 6 lines in the operated on eye, and 41 patients (82%) had improvement of at least 4 lines.

The mean (SD) target refraction based on preoperative calculations was -0.96 (0.17) D. The mean (SD) postoperative subjective refraction (spherical equivalent) 3 months after surgery was -1.04 (0.93) D. The difference between target refraction and subjective refraction was not statistically significant ( $P = .54$ , *t* test).

### INTRAOPERATIVE AND POSTOPERATIVE COMPLICATIONS

No significant intraoperative complications such as posterior capsule rupture, vitreous loss, zonulolysis, or aphakia were encountered in these 50 patients. Self-sealing wounds were achieved in all except 1 patient, who required 2 sutures to close the temporal main wound. Minor transient postoperative complications were encountered in 14 patients (Table 2). No adverse long-term effect on visual acuity was noted from these complications. At the 3-month follow-up, 9 patients (18%) had mild posterior capsular opacification, which was not visually significant and did not require laser capsulotomy. No endophthalmitis or significant postoperative inflammation was observed in this cohort of patients.

### SURGICALLY INDUCED ENDOTHELIAL CELL LOSS

The mean (SD) preoperative endothelial cell density per millimeter squared, coefficient of variation (an indicator of polymegathism), and percentage of hexagonal cells were 2522 (483), 0.376 (0.011), and 54.9% (1.5%), respectively (Table 3). The mean (SD) endothelial cell density squared, coefficient of variation, and percentage of hexagonal cells 3 months after surgery were 2424 (475), 0.379 (0.011), and 54.6% (1.6%), respectively. Therefore, there was a 3.9% loss of endothelial cells after surgery, which was statistically significant ( $P = .03$ , *t* test). The differences in coefficient of variation ( $P = .80$ ) and percentage of hexagonal cells ( $P = .88$ ) between baseline and 3 months after surgery were not statistically significant.

### SURGICALLY INDUCED ASTIGMATISM

The mean (SD) preoperative astigmatism, irrespective of axis, was 0.71 D (0.35 D). The mean (SD) postoperative astigmatism 3 months after surgery, irrespective of axis, was 0.93 D (0.65 D). The mean (SD) SIA in 50 patients was 0.69 D (0.98 D) at a mean axis of 11.1° calculated using the vector analysis method<sup>21</sup> based on preoperative and postoperative measurements and considering the axis.

### COMMENT

The present study describes a modified manual cataract extraction technique, SLIMCE, and its clinical outcomes. The postoperative visual acuity of this initial series of patients undergoing SLIMCE compared favorably with that in several recently published studies on manual SICS<sup>9-14,22</sup> and similar techniques.<sup>23</sup> In our study, all patients achieved BCVA of at least 20/60 (good outcome); 74% (37 patients) had BCVA of at least 20/30 at the 3-month follow-up.

Safety of the surgery was reflected by the absence of significant intraoperative complications, a low SIA (0.69 D), and a low rate (3.9%) of endothelial cell loss, which compared favorably with endothelial cell loss reported for phacoemulsification,<sup>20,24</sup> manual ECCE,<sup>20,25</sup> and manual SICS,<sup>20</sup> especially for large and dense cataracts. To our knowledge, this study is the first report on endothelial cell loss and SIA associated with SLIMCE.

A potential concern about the SLIMCE technique is postoperative endophthalmitis. While a large main wound may theoretically increase the risk of postoperative endophthalmitis, the use of a long (4-mm) sclerocorneal tunnel may reduce such complications.<sup>26</sup> In particular, 2 mm of the tunnel is located in the sclera, which greatly enhances the self-sealing property of the main wound. Moreover, the scleral incision was meticulously covered with conjunctiva at the end of the operation. All of these factors reduce the risk of postoperative endophthalmitis. In the present study, 98% (49 of 50 patients) of the wounds were self-sealing, and no cases of endophthalmitis were encountered.

Clinical outcomes of the present study demonstrated that the SLIMCE technique is safe and effective. Because the technique is independent of phacoemulsification machines, requires no sutures, and uses a polymethylmethacrylate IOL, it can be performed at low cost. The SLIMCE technique may provide a good method of cataract extraction that can be used in developing countries.

The major limitations of the present study include the short follow-up period, a small sample size, and the lack of direct comparison with other cataract surgery techniques such as phacoemulsification, manual ECCE, or SICS. In addition, all surgical procedures were performed by a single experienced surgeon (D.S.C.L.) in a tertiary eye hospital in a developed country.

It was important to demonstrate that this modified technique can be effectively mastered by less-experienced surgeons using basic equipment and under prevailing conditions in other settings. For this purpose, a prospective study<sup>27</sup> with 1-year follow-up results was performed in a clinical eye center in a rural area of Guangdong Province, China. Two local physicians who had no experience in performing microsurgery were trained to perform cataract extraction using the SLIMCE technique in a systematic manner. The structured training program included observation ( $\geq 100$  cases), wet laboratory training ( $\geq 100$  animal eyes), assistance at SLIMCE surgery ( $\geq 100$  cases), performance of SLIMCE surgery under close supervision ( $\geq 100$  cases), and assessment of 1 or more independent videos by a review board before certification as a SLIMCE surgeon. All surgical procedures were performed according to the standard steps as described herein with the use of locally made instruments, equipment, and consumables, including viscoelastic agents. Among 242 patients operated on by the 2 trained surgeons, 20/60 or better UCVA in the eye operated on was obtained in 83.4% and 20/60 or

better BCVA in 95.7%. The mean postoperative astigmatism did not differ between the eyes operated on and unoperated on. The study results confirm the effectiveness of skill transfer in this setting, with outcomes superior to those of most investigations in rural Asia.<sup>27</sup>

SLIMCE has the potential to serve as a safe and effective technique for cataract extraction to help reduce cataract blindness in developing countries. This study supplemented previous investigations and further demonstrated low rates of SIA and endothelial cell loss 3 months after surgery. Further large-scale studies on the safety and efficacy of SLIMCE and comparative trials between SLIMCE, ECCE, and SICS are warranted.

**Submitted for Publication:** May 14, 2008; final revision received December 17, 2008; accepted December 19, 2008.  
**Correspondence:** Dennis S. C. Lam, MD, FRCOphth, Department of Ophthalmology and Visual Sciences, The Chinese University of Hong Kong, Hong Kong Eye Hospital, Third Floor, 147K Argyle St, Kowloon, Hong Kong (dennislam\_pub@cuhk.edu.hk).

**Author Contributions:** Drs D. Lam, Rao, and Fan contributed equally to the study.

**Financial Disclosure:** None reported.

**Previous Presentations:** This study was presented in part at an instruction course and as a film festival video at the Annual Congress of the American Society of Cataract and Refractive Surgery; April 4-9, 2008; Chicago, Illinois.

**Additional Information:** A video is available online at <http://www.archophthalmol.com>.

## REFERENCES

1. *World Health Report 1998: Life in the 21st Century: A Vision for All*. Geneva, Switzerland: World Health Organization; 1998.
2. Thylefors B. A global initiative for the elimination of avoidable blindness. *Am J Ophthalmol*. 1998;125(1):90-93.
3. Yorston D. High-volume surgery in developing countries. *Eye*. 2005;19(10):1083-1089.
4. Zhao J, Sui R, Jia L, Fletcher AE, Ellwein LB. Visual acuity and quality of life outcomes in patients with cataract in Shunyi County, China. *Am J Ophthalmol*. 1998;126(4):515-523.
5. Limburg H, Foster A, Vaidyanathan K, Murthy GV. Monitoring visual outcome of cataract surgery in India. *Bull World Health Organ*. 1999;77(6):455-460.
6. Johnson GJ. Improving outcome of cataract surgery in developing countries. *Lancet*. 2000;355(9199):158-159.
7. Dondona L. Cataract surgery in very elderly patients: outcome of cataract surgery is poor in developing countries [comment]. *BMJ*. 2001;323(7310):455.
8. Brian G, Ramke J, Szetu J, Le Mesurier R, Moran D, du Toit R. Towards standards of outcome quality: a protocol for the surgical treatment of cataract in developing countries. *Clin Experiment Ophthalmol*. 2006;34(4):383-387.
9. Civerchia L, Apoorvananda SW, Natchiar G, Balent A, Ramakrishnan R, Green D. Intraocular lens implantation in rural India. *Ophthalmic Surg Lasers*. 1993;24(10):648-652.
10. Civerchia L, Ravindran RD, Apoorvananda SW, et al. High-volume intraocular lens surgery in a rural eye camp in India. *Ophthalmic Surg*. 1996;27(3):200-208.
11. Prajna NV, Chandrakanth K, Kim R, et al. The Madurai Intraocular Lens Study, II: clinical outcomes. *Am J Ophthalmol*. 1998;125(1):14-25.
12. Ruit S, Tabin GC, Nissman SA, Paudyal G, Gurung R. Low-cost high-volume extracapsular cataract extraction with posterior chamber intraocular lens implantation in Nepal. *Ophthalmology*. 1999;106(10):1887-1892.
13. Balent LC, Narendrum K, Patel S, Kar S, Patterson DA. High volume sutureless intraocular lens surgery in a rural eye camp in India. *Ophthalmic Surg Lasers*. 2001;32(6):446-455.

14. Venkatesh R, Muralikrishnan R, Balent LC, Prakash SK, Prajna NV. Outcomes of high volume cataract surgeries in a developing country. *Br J Ophthalmol*. 2005; 89(9):1079-1083.
15. Akura J, Kaneda S, Hatta S, Matsuura K. Manual sutureless cataract surgery using a claw vectis. *J Cataract Refract Surg*. 2000;26(4):491-496.
16. Singer JA. Frown incision for minimizing induced astigmatism after small incision cataract surgery with rigid optic intraocular lens implantation. *J Cataract Refract Surg*. 1991;17(suppl):677-688.
17. Akura J, Kaneda S, Hatta S, Matsuura K. Controlling astigmatism in cataract surgery requiring relatively large self-sealing incisions. *J Cataract Refract Surg*. 2000; 26(11):1650-1659.
18. Rao SK, Lam DS. A simple technique for nucleus extraction from the capsular bag in manual small incision cataract surgery. *Indian J Ophthalmol*. 2005;53 (3):214-215.
19. Hoffer KJ. Calculating endothelial cell loss. *J Cataract Refract Surg*. 1997; 23(1):6.
20. George R, Rupauliha P, Sriprya AV, Rajesh PS, Vahan PV, Praveen S. Comparison of endothelial cell loss and surgically induced astigmatism following conventional extracapsular cataract surgery, manual small-incision surgery and phacoemulsification. *Ophthalmic Epidemiol*. 2005;12(5):293-297.
21. Holladay JT, Moran JR, Kezirian GM. Analysis of aggregate surgically induced refractive change, prediction error, and intraocular astigmatism. *J Cataract Refract Surg*. 2001;27(1):61-79.
22. Hennig A, Kumar J, Yorston D, Foster A. Sutureless cataract surgery with nucleus extraction: outcome of a prospective study in Nepal. *Br J Ophthalmol*. 2003; 87(3):266-270.
23. Kimura H, Kuroda S, Mizoguchi N, Terauchi H, Matsumura M, Nagata M. Extracapsular cataract extraction with a sutureless incision for dense cataracts. *J Cataract Refract Surg*. 1999;25(9):1275-1279.
24. Hayashi K, Hayashi H, Nakao F, Hayashi F. Corneal endothelial cell loss in phacoemulsification surgery with silicone intraocular lens implantation. *J Cataract Refract Surg*. 1996;22(6):743-747.
25. Burgansky Z, Isakov I, Avizemer H, Bartov E. Minimal astigmatism after sutureless planned extracapsular cataract extraction. *J Cataract Refract Surg*. 2002; 28(3):499-503.
26. Cooper BA, Holekamp N, Bohigian G, Thompson PA. Case-control study of endophthalmitis after cataract surgery comparing scleral tunnel and clear corneal wounds. *Am J Ophthalmol*. 2003;136(2):300-305.
27. Lam DS, Congdon NG, Rao SK, et al. Visual outcomes and astigmatism after sutureless, manual cataract extraction in rural China: Study of Cataract Outcomes and Up-take of Services (SCOUTS) in the Caring Is Hip project, report 1. *Arch Ophthalmol*. 2007;125(11):1539-1544.

#### Ophthalmological Ephemera

In 1795, Dr Isaac Thompson concocted an eye water of zinc sulfate, saffron, camphor, and rose water. It was sold as late as 1939. This is 1 of a series of 32 medical trade cards advertising the product from 1875 through 1895.



### DR. ISAAC THOMPSON'S CELEBRATED EYE WATER,

FOR ALL COMPLAINTS OF THE EYES.  
*Each Bottle is stamped with my Proprietary Stamp. None other Genuine.*

#### THE GENUINE EYE WATER

Is enfolded in an engraved envelope, on which is the likeness of the Original Inventor, **DR. ISAAC THOMPSON**, New London, Conn., with a *fac-simile* of his signature; also the signature of **JOHN L. THOMPSON**, with a note of hand, signed by **JOHN L. THOMPSON**, 161 River Street, Troy, N. Y. *None other can be Genuine.*

This well-known and thoroughly efficient remedy has acquired a world-wide reputation, having been before the public for over eighty-five years, and it is a remarkable fact that its reputation has been sustained simply by the *merits of the medicine*, as the many thousands, who have used it, will bear testimony.

#### ITS MERITS STAND UNRIVALED.

In constant use since 1795.

Price.....25 Cents per Bottle.

**JOHN L. THOMPSON, Prop'r, Troy, N. Y.**

Courtesy of: Daniel M. Albert, MD, MS.